

Scientific Programme for the 26. ESC in Berlin, Germany 24 - 26 May 2017

e s c
e s c
european stroke conference

© #94137069/ christophkadur - Fotolia.com



ESC2017

26th EUROPEAN STROKE CONFERENCE

24-26 MAY 2017 | BERLIN | GERMANY

**Cerebrovascular
Diseases**

Cerebrovasc Dis 43/S1/17

Copyright: ©2017 S. Karger AG, Basel. All rights reserved

e-ISBN: 978-3-318-06071-3

e-ISSN: 1421-9786

P 117

Revisiting the nature of “dextrocerebral” neuropsychological symptomatology in patients with left middle cerebral artery (MCA) stroke – Dextrocerebral neuropsychological symptomatology is a range of higher mental functions impairments which are characteristic of right hemisphere damage

 M. Kovyazina¹, N. Varako², K. Fomina¹
¹Chair of Neuropsychology and Abnormal Psychology, Lomonosov Moscow State University, Moscow, Russian Federation

²Methodology of Psychology, Lomonosov Moscow State University, Moscow, Russian Federation

Introduction: The data regarding right hemisphere dysfunction symptoms included into neuropsychological syndromes of left hemisphere pathology is scarce. MCA supplies blood to lateral surface of both hemispheres, which in case of MCA stroke often results in a neuropsychological syndrome with a complex of speech impairments, acoustic and visuospatial gnosis defects and praxis disorders at its center. Modality-specific memory disorders play a special part. **Objectives:** To identify disorders of higher mental functions characteristic of right hemisphere brain damage as a result of left MCA stroke. **Patients and methods:** Luria’s methods of neuropsychological assessment were used to examine 30 subjects with acute left MCA cerebrovascular events (20 males and 10 females, age 44 to 66), 20 of whom had ischemic stroke and 10 — hemorrhagic stroke. **Results:** Among “dextrocerebral” symptoms observed after left MCA stroke the most frequent are difficulties in reproducing the order of memorized stimuli in the mnestic sphere. At the same time, incomplete reproduction of the volume of memorized stimuli is rarely represented by serial position effect. Visuospatial perception assessment procedures reveal difficulties in conveying spatial perspective, projection (especially when drawing complex geometric shapes from memory), metric errors. Structural and topological mistakes, excessive realism in drawings of subject pictures and fragmentary copying strategy are less frequent. In reasoning tasks (telling a story based on a picture story) misunderstanding of the situational context of the plot is often observed. The group of patients with hemorrhagic stroke showed significantly fewer and less severe “dextrocerebral” symptoms than the group with ischemic stroke. **Conclusion:** “Dextrocerebral” symptomatology has diffuse character. However, its expression may be observed to have a tendency towards symmetry to the left hemisphere focus of the stroke. The emergence of such symptoms may be explained by mobilization of adaptive processes, which are regulated by the right hemisphere, which results in “robbing” the right hemisphere of its functionality.

P 118

Early neurocognitive development data in infants with arterial ischemic stroke

S. Kiselev, O. Lvova, E. Suleimanova

Laboratory of Brain and Neurocognitive Development, Ural Federal University, Yekaterinburg, Russian Federation

Introduction: Paediatric Arterial Ischemic Stroke (PedAIS) is rare and severe disorder, which leads to motor and mental delay. At the same time, the approaches related to PedAIS impairment and outcome options are not standardized, a few scales and questionnaires have been used, the results could be compared rarely. **Aim:** The aim of the study was to investigate the influence of PedAIS on early neurocognitive development in infants using the Bayley Scales of Infant and Toddler Development. **Methods:** Case-control study. Totally 38 infants aged 6-14 months were enrolled. 19 infants who have had PedAIS within the first year of life were evaluated at the recovery period, 3-5 months later (Stroke group, mean age 8,17±2,61 months). PedAIS was confirmed by brain MRI. The control group included 19 children, term, with normal developmental milestones (mean age 8,35±2,42 months, Controls). All patients signed informed consent form. Participants in both groups were matched for gender and age. The Bayley Scales of Infant and Toddler Development (3rd Edition) were used to evaluate the neurocognitive abilities in those infants. **Results:** The AN-COVA with age as a covariate has revealed that Stroke group infants performed significantly more poorly ($p \leq 0,05$) than Controls on “cognitive subscale” (Fisher 31,07), “receptive language subscale” (Fisher 22,13) and “gross motor subscale” (Fisher 27,69) of the Bayley Scales. There were no significant differences between infants from Stroke group and Controls on “expressive language subscale” and “fine motor subscale”. **Conclusion:** It has been proposed that PedAIS has a specific, but not a global, negative effect on the neurocognitive development within the first year of life. This work was supported by grant Russian Science Foundation 17-15-01144

P 119

Neuropsychological symptomatology of brain vascular pathology

M. Kovyazina, T. Starostina

Psychology, Lomonosov Moscow State University, Moscow, Russian Federation

Introduction: Dichotic listening is a sensitive method used for evaluation of cerebral dysfunction caused by different brain diseases (including stroke cases). “Lesion” effect is observed in patients with unilateral tumorous brain damage during audio-verbal dichotic stimuli perception: the left-brain injured patients show the decrease in the left ear-accuracy scores and the right-brain injured patients show the increase in the right ear-accuracy scores. We consider that the localization of the injury of specific brain area can be defined by right- and left ear-accuracy that is why the research into vascular etiology syndrome including neuropsychological aspect is actual. **Method:** 40 subjects participated in the study (20 normal controls, 20 patients with brain damage, age range 19-62 years). All the participants were right-handed. Out of 9 left-brain injured patients 8 had brain tumor (including 2 patients with frontal tumors, 6 patients with temporal lobe tumors (3 of them had aphasia)), 1 patient suffered an ischemic stroke (basal nuclei area; left middle cerebral artery (MCA) circulation). Out of 11 right-brain injured patients 10 had brain tumors (including 5 patients with frontal tumors, 4 patients with temporal lobe tumors, 1 patient with parietal-occipital lobe tumor), 1 patient suffered an ischemic stroke (the central branch of the MCA). The participants were presented with consonant-vowel syllable dichotic listening. **Results:** The three out of the four patients with right temporal lobe tumor showed the increase in the right ear-accuracy scores and the decrease in the left ear-accuracy scores (the more extensive and combined the injury is the more pronounced the effect is). Also high right-ear accuracy score was noticed in the patient with temporal lobe tumor, but the value corresponded to the normal condition. Besides, the same effect was observed in the two out of the five patients with right frontal lobe tumor, although it was less pronounced. Not only the decrease in right ear-accuracy scores and the accuracy increase in the left ear, but aphasia were observed in the three out the six patients with left temporal lobe tumor (including combined injury: temporal-parietal lobe and temporal-frontal lobe). Aphasia and “lesion” effect weren’t noticed in the remaining three patients. The two patients suffered an ischemic stroke didn’t show “lesion” effect. **Conclusions:** The direct transfer of neuropsychological “local” symptomology to the clinic of vascular diseases characterized by diffuse mechanisms and clinical implications is incorrect. Even classic “local” symptoms can acquire specific features in neuropsychological syndromes of vascular pathology.

L 004

Improvement of cognitive function in early stage of Vascular Cognitive Impairment (VCI) after treatment with the acetylcholine precursor choline alfoscerate

Y. Yang

Neurology, VHS Medical Center, Seoul, South Korea

Backgrounds: Several studies have reported cholinergic deficits in brain and cerebrospinal fluid of patients with vascular dementia (VaD). In view of this, cholinergic agents were proposed for relieving symptoms of VaD. Preclinical studies, have documented that choline alfoscerate increases the release of acetylcholine in rat hippocampus, facilitates learning and memory, counters cognitive deficit in experimental models of aging brain. This study therefore evaluated whether treatment with the acetylcholine precursor choline alfoscerate improved the cognitive abilities in patients with early stage of VCI. **Methods:** Totally, 60 participants (early stage of VCI) participated in this study. To test the effectiveness of treatment with the acetylcholine precursor choline alfoscerate to cognition, all patients were randomly allocated to either an intervention group (n=30) or a control group (n=30). Two matched groups were compared: intervention group treated with donepezil (10mg/day) plus choline alfoscerate (1200mg/day), and control group treated with donepezil (10mg/day). The intervention group were treated with choline alfoscerate (400-mg capsules), 3 times daily, for 180 days. Efficacy outcome measures that were assessed at the beginning of the investigation and after 180 days of treatment included scores the Mini-Mental State Examination (MMSE), the Global Deterioration Scale (GDS), the Korean-Boston Naming Test (K-BNT), the Rey Complex Figure test (RCFT), the Controlled Oral Word Association Test (COWAT), the Korean-Color Word Stroop Test (K-CWST). **Results:** After 6 months, the intervention group showed a significant change in language of K-MMSE, compared with the baseline cognitive examinations. Also, there was greater improvement in language, attention, calculation, verbal memory, and frontal function for the intervention group, as compared with controls. **Discussion:** The results of this study suggest the clinical usefulness and beneficial effects on the general cognitive functions of acetylcholine precursor choline alfoscerate in the treatment of the cognitive symptoms of early stage of VCI. **Key Words:** Acetylcholine precursor choline alfoscerate, Cognition.

Neuropsychological assessment of white matter pathology in patients with cerebrovascular diseases

M. Kovyazina, K. Fomina

Chair of Neuropsychology and Abnormal Psychology, Lomonosov Moscow State University, Moscow, Russian Federation

Introduction: According to WHO, stroke and ischemia rank as the third leading cause of death. Functional impairment of conduction tracts, specifically leukoaraiosis, is one of the pathologic features of cerebrovascular pathology. Given that white matter damage is the predictor of transition from normal physical function to complete disablement within one year, and the impairment develops through cognitive and motor function decline, research in this field is important for neuropsychological assessment and rehabilitation. **Objectives:** While neuropsychology has a range of methods for topical diagnosis of grey matter damage, there are no tools or experimental methodology for white matter pathology research (i.e. commissural system and intrahemispheric connections enabling inter-analyzer interaction (IAI)). Due to existing demand from practical medicine and clinical neuropsychology it is essential to develop a neuropsychological method for assessment of cerebral conduction tracts' functional status. **Materials and methods:** Uznadze's method of fixed set can be applied for this purpose, as irradiation of set from one modality to another is impossible without inter-analyzer intra- and interhemispheric connections. Set forming experiments are conducted using visual modality: the research subject is asked to compare circumferences with different diameters placed in different visual semifields. Critical experiments are conducted using haptic modality: the subject is asked to compare spheres of the same volume placed in both hands. The amount of haptic illusions is indicative of IAI characteristics. **Results:** Pre-experimental research design included two patients with white matter pathology (patient G., male, 27, full agenesis of CC, based on MRI results; patient N., female, 57, supratentorial lesions produced by gliosis of ischemic nature, based on MRI results) and two healthy subjects (both male, 35). The patients showed a rapid decrement of set, which manifested in one contrast haptic illusion in patient G. and three such illusions in patient N. The healthy subjects showed 15 and 17 illusions respectively. **Conclusion:** The method of fixed set is especially relevant as an important means of researching the conduction tracts function in patients with cerebrovascular pathology.

Figure 1

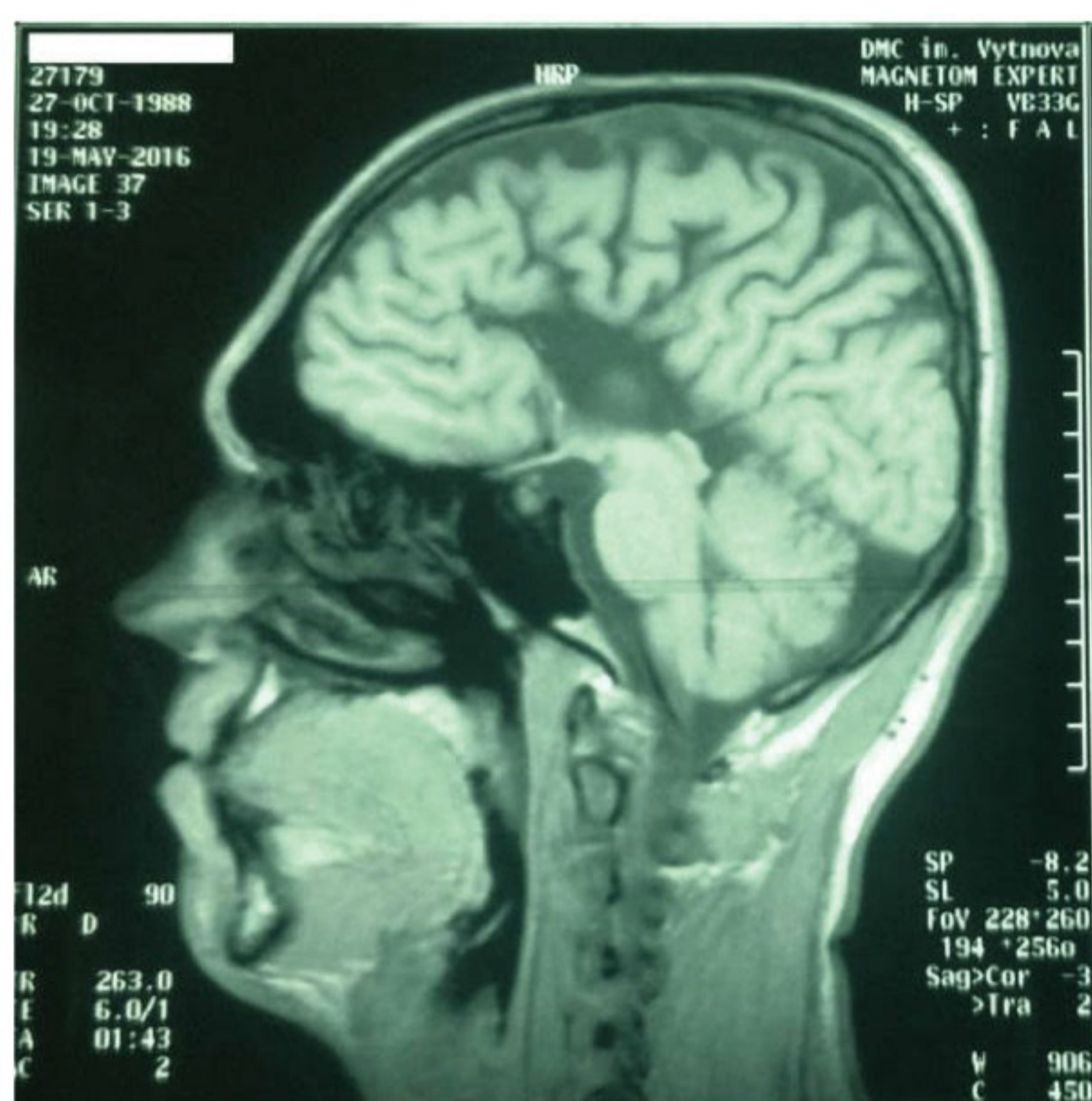



Figure 2



P 337

Surgical treatment of epileptogenic cavernous malformations

A. Smolanka, T. Havryliv, V. Smolanka

Regional Centre of Neurosurgery and Neurology, Uzhhorod, Ukraine

Background: The most frequent symptom of cavernous malformations of the brain is seizure, which is seen in 40-80% of cases. The risk of seizure onset in patients with supratentorial cavernous malformation is 1.4-2.8% per year. **Methods:** 35 patients with supratentorial cavernous malformations underwent surgery in Uzhhorod Regional Centre of Neurosurgery and Neurology between November, 2010 and November, 2016. We studied outcome of 26 patients who presented with seizure (74.3%). Their postoperative follow up was of 3 to 74 months (mean 32.2 months). Male to female ratio was 6:7. Mean age of the patients was 30.6 years. Localisation of the lesions: frontal lobe - 14 patients (53.8%), temporal lobe - 7 patients (26.0%), parietal lobe - 3 cases (11.5%) insula and occipital lobe - 1 patient each (3.8%). 12 patients had complex partial seizures (46.2%) and in 11 cases we observed secondary-generalised seizures (42.3%). Simple partial seizures were rare (11.5%). An EEG was performed in all cases - lesions were concordant with MRI. All patients underwent microsurgical resection of cavernous malformations with perifocal hemosiderosis. Follow-up MRI (3 months after surgery) showed complete resection of lesion in all cases. **Results:** Patients were divided into two groups: with rare seizures (less than 10 seizures before surgery) - 12 cases (46.2%); and with chronic epilepsy (>10 seizures before surgery) - 14 cases (53.8%). Outcome was assessed according to Engel scale: Engel I - 21 patients (80.8%), Engel II - 3 patients (11.5%), Engel III and IV - 1 patient each (3.8%). The subgroup analysis showed that excellent outcome was achieved in patients with rare seizures - 100% seizure-free (Engel I). Further analysis showed that both patients with unsatisfactory result (Engel III and IV) had preoperative secondary-generalised seizures and drug-resistant epilepsy. Age, sex and localisation of the lesion did not affect the outcome. None of the patients deteriorated after surgery. **Conclusions:** Surgical treatment of epileptogenic cavernous malformations is safe (morbidity/mortality - 0) and effective (Engel I+II - 92.3%). Negative prognostic factors are long duration of the disease before surgery, secondary-generalised seizures and drug-resistant epilepsy.

P 338

Surgical treatment of carotid artery stenosis

T. Tsukahara, S. Fukuda

Neurosurgery, NHO Kyoto Medical Center, Kyoto, Japan

Background and purpose: We have two surgical methods for the treatment of severe carotid stenosis, although the choice of carotid endarterectomy (CEA) or carotid artery stenting (CAS) has not been established. This report presents appropriate treatment strategy using plaque diagnosis and the clinical results of CEA and CAS. **Materials and methods:** From January 2001 to December 2016, we surgically treated carotid stenosis in 291 lesions by CEA and 335 lesions by CAS. CEA was the first choice for the patients with soft atherosclerotic plaques and severe calcified plaques after plaque diagnosis was made by carotid ultrasonography (carotid US) and black blood magnetic resonance imaging (BB-MRI). **Results:** Stenosis of carotid arteries was relieved in all cases after CEA or CAS. Perioperative mortality with CEA and CAS was 0.3% (1/291) and 0.3% (1/335), respectively. Morbidity by ischemic stroke with CEA and CAS was 2.4% (7/291) and 2.0% (5/335), respectively. Surgical morbidity was not high in patients with medical risk factors. **Conclusions:** Carotid stenotic lesions can be treated with comparably low morbidity and mortality rates using CEA and/or CAS even with high risks, when appropriate surgical methods are selected considering each characteristic of carotid stenosis using plaque diagnosis.

P 339

Novel indirect revascularization technique with preservation of temporal muscle function for moyamoya disease

K. Noguchi, T. Aoki, A. Hashimoto, N. Itou, T. Negoto, K. Orito, M. Hirohata, M. Morioka

Department of Neurosurgery, Kurume University School of Medicine, Kurume Fukuoka, Japan

Introduction: Usually we perform the indirect revascularization for symptomatic Moyamoya disease in expectation of angiogenesis. But conventional method of indirect revascularization including EMS • EDAMS have some disadvantages, 1; Mass effect from the muscle associated increase in intracranial pressure. 2; Cosmetic problems coming from hollow temporal region. In order to solve these problems, we devised new surgical method of indirect revascularization that use only temporal fascia but not temporal muscle. There are some important techniques in this way. **Methods:** The skin incision was performed along the STA and additional incision was performed in posterior direction to obtain temporal fascia widely. Temporal fascia and muscle were dissected separately. The base of vascularized flap of fascia and muscle were made at posterior side and anterior side respectively. Craniotomy and EDS were performed in conventional way. Only Temporal fascia was laid on the brain surface and used as duraplasty. The temporal muscle is reconstructed anatomically right position. **Results:** We performed this method for consecutive 18 cases (21 hemispheres) between 2012 and 2016. In all cases but one, the symptoms and CBF improved, and DSA showed the satisfactory angiogenesis. Only 1 case had wounds problem. The depressed temporal region and atrophy of temporal muscle are less, in comparison with conventional way of EMS. **Conclusions:** In previous study and this study, we observed the angiogenesis of EMS was originated from fascia. Thus this method is considered an excellent procedure for both angiogenesis and post-operative function. But the observation number is limited and shot observation period, it will be thought that long-term examination is necessary.